Disease threats to wild and cultured abalone in Australia

Cecile Dang[A,B] *and Terrence L Miller*[A,C]

[A]Fish Health Laboratory, Department of Fisheries Western Australia, 3 Baron-Hay Court, South Perth, WA 6151, Australia

[B]Faculty of Science and Engineering, School of Science, Department of Environment and Agriculture, Curtin University, Bentley, WA 6102, Australia. Email: cecile.dang@fish.wa.gov.au

[C]Centre for Sustainable Tropical Fisheries and Aquaculture, College of Marine and Environmental Science, James Cook University, Cairns, Qld 4878, Australia. Email: terry.miller@fish.wa.gov.au

Abalone species are important for recreational and commercial fisheries and aquaculture in many jurisdictions in Australia. Clinical infections with viral, bacterial and parasitic pathogens can cause significant losses of wild and cultured stock, and subclinical infections may result in decreased productivity and growth. Infections with abalone herpesviruses (AbHV), *Vibrio* spp. and parasites of the genus *Perkinsus* are of particular concern to Australian fisheries. Here we provide a brief overview of these three major pathogen groups and their diagnoses from an Australian perspective.

Perkinsus olseni

The protistan parasite *Perkinsus olseni*, was first described as a parasite of the abalone, *Haliotis rubra*, in the south of Australia[1]. *P. olseni* belongs to the order Perkinsida and is the causative agent of perkinsosis, a disease associated with extensive mortalities of molluscs worldwide[2–5]. *P. olseni* is included on the list of reportable disease of the World Organisation for Animal Health (OIE) because infections cause mass mortalities in oysters and clams and significant economic losses (http://www.oie.int/animal-health-in-the-world/oie-listed-diseases-2016/). *P. olseni* is also listed on the Network of Aquaculture Centres in Asia-Pacific (NACA). This parasite induces lesions that can impede the respiration, and other physiological processes such as growth and reproduction, sometimes leading to death, impacting fishery and aquaculture productivity[6–8].

P. olseni has three main life stages. The trophozoite stage occurs in the tissues of the live host and proliferate by undergoing successive bipartitionning (schizogony) that yields up to 32 daughter cells (Figure 1)[9,10]. The rupture of the wall allows the liberation of immature trophozoites that will enlarge[9,10]. In the dying host, trophozoites gradually enlarge and become mature trophozoite or prezoosporangia. When released in the water column and under favourable environmental conditions, the prezoosporangia divide internally into hundreds of biflagellated ellipsoidal zoospores that are formed within the original cell wall and leave the zoosporangium via a discharge tube. The motile zoospores can then infect a new host. It is not yet well understood which stage is the most effective or principal stage for transmitting the disease in the natural environment[11].

In the 1970s, soft white-yellow abscesses were observed in the flesh of the blacklip abalone *Haliotis rubra* collected in South Australia[10]. When clusters of *Perkinsus* cells are found near the surface of the abalone, they appear as a soft white nodule or microabscess[10]. Microabscesses develop to form brown spherical abscess or pustules up to 8 mm or more in diameter[10]. These abscesses are observed in the foot and muscle[10]. Identical lesions were observed in *H. laevigata* but lesions are absent in infected *H. scalaris* and *H. cyclobates*[10]. This parasite was associated with severe mortalities in *H. laevigata* wild populations in 1980s, leading to local extinction on the western shore of Gulf St Vincent, South Australia[10,12]. Outbreaks also occurred during the same period in *H. laevigata* aquaculture facilities in South Australia, when 40% of the stock died.

Mass mortalities of blacklip abalone (*H. rubra*) occurred from 1992 to 2002 along approximately 500 km of the NSW coastline between Port Stephens and Jervis Bay[13]. Histological examination of moribund abalone since 1992 and a survey of infection prevalence in abalone using Ray's test in 2002, confirmed infections by a variant strain of *P. olseni*, suggesting that this parasite contributed to the mortalities observed[13]. Indeed, substantial tissue and organ damage occurred in abalone with high intensity of infection. Disruption of the gut epithelium and infarction in the gills suggested impairment

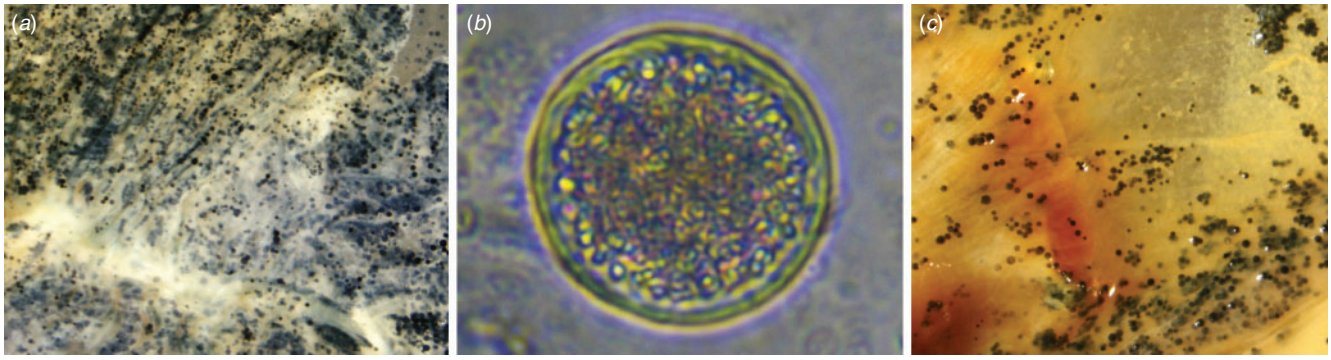

Figure 1. *In situ* iodine stained trophozoites of *Perkinsus* sp. (black dots) in the gills (*a*) and mantle (*c*) of heavily-infected Manila clams (*Ruditapes philippinarum*). Prezoosporangium containing hundreds of zoospores isolated from the gills of greenlip abalone (*H. laevigata*) in Western Australia (*b*).

to normal nutrient absorption and respiration[14]. There is some indication that stress such as that from high temperatures exacerbate the disease but the conditions under which the disease progresses are not well understood.

Perkinsus olseni was formally identified and reported in Western Australia in 2015 from wild greenlip abalone. Surveys of wild and cultured abalone stocks in WA are currently ongoing to evaluate the prevalence of this parasite and monitor any potential negative impacts.

Abalone herpesvirus infections

Infections with herpes-like viruses resulting in the disease Abalone Viral Ganglioneuritis (AVG), were first identified and characterised in Australia around 2005 from Victorian land-based greenlip abalone (*H. laevigata*) culture facilities[15]. The disease is listed as reportable by the OIE and NACA and is characterised by marked inflammation and necrosis of nervous tissues (cerebral, pleuropedal and buccal ganglia, branches of the pedal nerve and peripheral nerves) in infected abalone[15–17]. Since their initial detection, abalone herpesvirus (AbHV) infections have been implicated in causing mass mortalities in wild abalone stocks in Victoria and in culture facilities in Tasmania, resulting in strict stock movement restrictions and enhanced biosecurity practices being enforced by jurisdictions[15,16,18,19]. Five genotypic variants of AbHV have now been identified from Australian *Haliotis conicopora*, *H. laevigata* and *H. rubra* populations, and experiments have confirmed that all five variants may cause disease and subsequent mortalities in these abalone species[18,20,21].

Diagnosis of AbHV infections in abalone typically involves histopathological examination of neural tissues, electron microscopy and nucleic acid sequencing[17,18,21,22]. Rapid quantitative real-time PCR assays targeting the five Australian AbHV variants have been developed by the Fish Disease Laboratory at the Australian Animal Health Laboratory to aid in quickly assessing presence or absence of virus in abalone stocks for biosecurity and translocation protocols by relevant jurisdictions[21,23].

Vibrio spp. infections

Infections with *Vibrio* spp. have been implicated in causing severe mass mortalities in cultured abalone in numerous localities worldwide, including Australia[24]. These pathogens are generally considered opportunistic, causing acute infection and mortality in physically or environmentally stressed individuals[25–27]. The condition 'Summer Mortality Syndrome' observed in Australian greenlip (*H. laevigata*) and blacklip (*H. rubra*) abalone and their hybrids, refers to an increase in mortalities in association with increased water temperatures which promote infection with *Vibrio* species such as *V. harveyi*[28].

Confirmative diagnosis for *Vibrio* spp. infection in abalone includes observing bacteria within affected tissues on histopathological examination of moribund abalone, isolation and culture of bacteria followed by matrix-assisted laser desorption ionisation time of flight mass spectrometry (MALDI-TOF) or DNA sequencing[29].

References

1. Lester, R.J.G. and Davis, G.H.G. (1981) A new *Perkinsus* species (Apicomplexa, Perkinsea) from the abalone *Haliotis ruber*. *J. Invertebr. Pathol.* **37**, 181–187. doi:10.1016/0022-2011(81)90073-2
2. Choi, K.S. and Park, K.I. (1997) Report on the occurrence of *Perkinsus* sp. in the Manila clams, *Ruditapes philippinarum* in Korea. *Journal of Aquaculture* **10**, 227–237.
3. Goggin, C.L. and Lester, R.J.G. (1987) Occurrence of *Perkinsus* species (Protozoa, Apicomplexa) in bivalves from the Great Barrier Reef. *Dis. Aquat. Organ.* **3**, 113–117. doi:10.3354/dao003113
4. Hamaguchi, M. *et al*. (1998) *Perkinsus* protozoan infection in short-necked clam *Tapes* (=*Ruditapes*) *philippinarum* in Japan. *Fish Pathol.* **33**, 473–480. doi:10.3147/jsfp.33.473
5. Park, K.I. and Choi, K.S. (2001) Spatial distribution of the protozoan parasite *Perkinsus* sp. found in the Manila clams, *Ruditapes philippinarum*, in Korea. *Aquaculture* **203**, 9–22. doi:10.1016/S0044-8486(01)00619-6
6. Park, K.I. *et al*. (2006) Application of enzyme-linked immunosorbent assay for studying of reproduction in the Manila clam *Ruditapes philippinarum* (Mollusca: Bivalvia) II. Impact of *Perkinsus olseni* on clam reproduction. *Aquacult. Res.* **251**, 182–191. doi:10.1016/j.aquaculture.2005.06.003
7. Casas, S.M. and Villalba, A. (2012) Study of perkinsosis in the grooved carpet shell clam *Ruditapes decussatus* in Galicia (NW Spain). III. The effects of *Perkinsus olseni* infection on clam reproduction. *Aquaculture* **356-357**, 40–47. doi:10.1016/j.aquaculture.2012.05.038

8. Dang, C. *et al*. (2013) Correlation between perkinsosis and growth in clams *Ruditapes* spp. *Dis. Aquat. Organ.* **106**, 255–265. doi:10.3354/dao02640
9. Villalba, A. *et al*. (2004) Perkinsosis in molluscs: a review. *Aquat. Living Resour.* **17**, 411–432. doi:10.1051/alr:2004050
10. Goggin, C.L. and Lester, R.J. (1995) *Perkinsus*, a protistan parasite of abalone in Australia: a review *Mar. Freshwater Res.* **46**, 639–646. doi:10.1071/MF9950639
11. Chu, F.L.E. (1996) Laboratory investigations of susceptibility, infectivity, and transmission of *Perkinsus marinus* in oysters. *J. Shellfish Res.* **15**, 57–66.
12. O'Donoghue, P.J. *et al*. (1991) *Perkinsus* (Protozoa: Apicomplexa) infections in abalone from South Australia waters. *Trans. R. Soc. S. Aust.* **115**, 77–82.
13. Liggins, G.W. and Upston, J. (2010) Investigating and managing the Perkinsus-related mortality of blacklip abalone in NSW. FRDC Project No. 2004/084. Industry & Investment NSW – Fisheries Final report series No. 120.
14. Callinan, R. and Landos, M. (2006) New South Wales report, Department of Primary Industries. Abalone aquaculture subprogram: A national survey of diseases of commercialy exploited abalone species to support trade and translocation issues and the development of health surveillance programs (Handlinger, J. *et al*. eds), FRDC project report 2002/201, Tasmanian Aquaculture and Fisheries Institute, Hobart, 68–83.
15. Hooper, C. *et al*. (2007) Ganglioneuritis causing high mortalities in farmed Australian abalone (*Haliotis laevigata* and *Haliotis rubra*). *Aust. Vet. J.* **85**, 188–193. doi:10.1111/j.1751-0813.2007.00155.x
16. Appleford, P. *et al*. (2008) Abalone viral ganglioneuritis in south eastern Australia – a wake up call. *J. Shellfish Res.* **27**, 986.
17. Hooper, C. *et al*. (2012) Leucopenia associated with abalone viral ganglioneuritis. *Aust. Vet. J.* **90**, 24–28. doi:10.1111/j.1751-0813.2011.00877.x
18. Crane, M.S. *et al*. (2013) Evaluation of abalone viral ganglioneuritis resistance among wild abalone populations along the Victorian coast of Australia *J. Shellfish Res.* **32**, 67–72. doi:10.2983/035.032.0112
19. Baulch, T. *et al*. (2013) Tasmanian Abalone Biosecurity Project: implementation phase 1: biosecurty strategies for abalone processors. *J. Shellfish Res.* **32**, 33–35. doi:10.2983/035.032.0107
20. Corbeil, S. *et al*. (2012) Abalone herpes virus stability in sea water and susceptibility to chemical disinfectants. *Aquaculture* **326–329**, 20–26. doi:10.1016/j.aquaculture.2011.11.031
21. Corbeil, S. *et al*. (2016) Australian abalone (*Haliotis laevigata, H. rubra* and *H. conicopora*) are susceptible to infection by multiple abalone herpesvirus genotypes. *Dis. Aquat. Organ.* **119**, 101–106. doi:10.3354/dao02989
22. Chang, P.H. *et al*. (2005) Herpes-like virus infection causing mortality of cultured abalone Haliotis diversicolor supertexta in Taiwan. *Dis. Aquat. Organ.* **65**, 23–27. doi:10.3354/dao065023
23. Corbeil, S. *et al*. (2010) Development and validation of a TaqMan (R) PCR assay for the Australian abalone herpes-like virus. *Dis. Aquat. Organ.* **92**, 1–10. doi:10.3354/dao02277
24. Bower, S.M. (2003) Update on emerging abalone diseases and techniques for health assessment. *J. Shellfish Res.* **22**, 805–810.
25. Hooper, C. *et al*. (2011) Effect of movement stress on immune function in farmed Australian abalone (hybrid *Haliotis laevigata* and *Haliotis rubra*). *Aquaculture* **315**, 348–354. doi:10.1016/j.aquaculture.2011.02.012
26. Hooper, C. *et al*. (2014) Effects of severe heat stress on immune function, biochemistry and histopathology in farmed Australian abalone (hybrid *Haliotis laevigata* × *Haliotis rubra*). *Aquaculture* **432**, 26–37. doi:10.1016/j.aquaculture.2014.03.032
27. Nicolas, J.L. *et al*. (2002) *Vibrio carchariae*, a pathogen of the abalone *Haliotis tuberculata*. *Dis. Aquat. Organ.* **50**, 35–43. doi:10.3354/dao050035
28. Dang, V.T. *et al*. (2011) Variation in the antiviral and antibacterial activity of abalone *Haliotis laevigata, H. rubra* and their hybrid in South Australia. *Aquaculture* **315**, 242–249. doi:10.1016/j.aquaculture.2011.03.005
29. Schikorski, D. *et al*. (2013) Development of TaqMan real-time PCR assays for monitoring *Vibrio harveyi* infection and a plasmid harbored by virulent strains in European abalone *Haliotis tuberculata* aquaculture. *Aquaculture* **392–395**, 106–112. doi:10.1016/j.aquaculture.2013.02.005

Biographies

Cecile Dang is a Principal Research Scientist with the Department of Fisheries Western Australia and heads the WA Fish Health Laboratory. Much of her research is focused on host/pathogen dynamics and immune response. She has worked extensively with diseases and parasites of wild and commercially important mollusc species.

Terrence L Miller is a Senior Research Scientist with the Department of Fisheries Western Australia and runs the molecular diagnostics section of the WA Fish Health Laboratory. His initial training was in the ecology and systematics of parasites of fish, but has broadened his research interests to include parasites and diseases of fish and crustaceans of commercial and recreational significance.